

3-Adjuvant role of one hundred twenty eight multidetector computed tomography in categorizing adnexal masses

Manuscript Number: EJRNM-D-18-00268R3

Title: Adjuvant role of one hundred twenty eight multidetector computed tomography in categorizing adnexal masses

Article Type: Research Paper

Keywords: Adnexal masses; MDCT and ovarian neoplasms

Corresponding Author: Dr. Elshaimaa M. Mohamed, M.D.

Corresponding Author's Institution: Zagazig university faculty of medicine

First Author: Elshaimaa M. Mohamed, M.D.

Order of Authors: Elshaimaa M. Mohamed, M.D.; Hend I AbdElrahim, Msc; Hamada m Khater, M.D.; Amr A Abdelrhman, M.D.; Hanaa m Ibrahim, M.D.

Abstract: AIM: To assess the role of a 128 MDCT in discrimination between the benign and malignant adnexal masses.

PATIENTS AND METHODS: Retrospective review of the preoperative MDCT results of fifty women with clinically or sonographically diagnosed adnexal masses had been done by blinded radiologists to the surgical and histopathological outcomes. We excluded patient with bilateral ovarian masses, associated breast carcinoma with metastatic disease and postoperative patients. Our participants scanned by 128-row MDCT with its Maximum Intensity Projection, Multiplanar Reformatting and Volume Rendering Imaging. Later, the outcome of MDCT compared with surgical and pathological results.

RESULTS: The mean age of patients was 52 years old. MDCT diagnosed 23 (46%) benign masses and 27 (54%) malignant masses. 128-row MDCT presented sensitivity, specificity and diagnostic accuracy values 100%, 95.8% and 98% respectively in discriminating malignant from benign adnexal masses compared to histopathology. Our study revealed an excellent agreement 1.0 between the MDCT and laparoscopy as a proof of the origin of adnexal mass 100%.

CONCLUSIONS:

128 MDCT provides a precise distinction of ovarian from extraovarian pelvic masses and a dependable discrimination between benign and malignant adnexal mass lesions. We recommend advance 128 MDCT as an excellent reliable imaging technique to categorize adnexal masses.

Title : Adjuvant role of one hundred twenty eight multidetector computed tomography in categorizing adnexal masses

Authors: ElShaimaa Mohamed Mohamed,M.D^{a*}, Hend Ibrahim
Abdelrahim,Msc^a, Hamada Mohamed Khater,M.D^b, Amr Ahmed
Abdelrhman,M.D^c, Hanaa M. Ibrahim,M.D^d

^a Department of Radiodiagnosis, Faculty of Medicine, Zagazig University, Egypt.

^b Department of Radiodiagnosis, Faculty of Medicine, Banha University, Egypt.

^c Department of Obstetrics and Gynaecology, Faculty of Medicine, Zagazig University, Egypt.

^d Department of Pathology, Faculty of Medicine, Zagazig University, Egypt.

Correspondent:

Name: ElShaimaa Mohamed Mohamed,M.D.

Address: Department of Radiodiagnosis, Faculty of Medicine, Zagazig University,
Zagazig, Sharkia, 44519, Egypt.

Tel.:0020 1005515964.

E-mail address: bosy.radiology@gmail.com

Contributing authors:

- **ElShaimaa M. Mohamed, M.D:**

Address: Department of Radiodiagnosis, Faculty of Medicine, Zagazig University, Egypt.

Email: bosy.radiology@gmail.com

- **Hend Ibrahim AbdElrahim, Msc:**

Address: Department of Radiodiagnosis, Faculty of Medicine, Zagazig University, Egypt.

Email: Hendmido64@gmail.com

- **Hamada Mohamed Khater, M.D:**

Address: Department of radiodiagnosis, Faculty of Medicine, Banha University, Egypt.

Email: Drhamadakhater@gmail.com

- **Amr Ahmed Abdelrhman, M.D:**

Address: Department of Obstetrics and Gynaecology, Faculty of Medicine, Zagazig University, Egypt.

Email: Amrrobot@gmail.com

- **Hanaa M. Ibrahim, M.D:**

Address: Department of Pathology, Faculty of Medicine, Zagazig University, Egypt.

Email: Dr.hanaaghatwary@gmail.com

Conflict of Interest:

All authors certify that they have no affiliations with or involvement in any organization or entity with any financial interest (such as honoraria; educational grants; participation in speakers' bureaus; membership, employment, consultancies, stock ownership, or other equity interest; and expert testimony or patent-licensing arrangements), or non-financial interest (such as personal or professional relationships, affiliations).

-The institution from which the work originates: Department
of Radiodiagnosis, Faculty of Medicine, Zagazig
University, Egypt.

Informed Patient Consent:

All patients have consented to submission their data and imaging reports to the journal.

Author Agreement

All authors of this research agree to submit in your journal.

Elshaimaa M. Mohamed as a corresponding author.

Hend I. Abdelrhim.

Hamada M. Khater.

Amr A. Abdelrahman.

Hanaa M. Ibrahim

***Detailed Response to Reviewers**

First of all, many thanks for your great effort in reviewing our research and also we appreciate your valuable meticulous comments.

We reply and explain our responses on your precise comments:

Reviewers comments:

- 1- We are rewriting the references after reviewing the author guidelines of EJRNM and highlighted in red color. We hope that reference styling accepted from you.
- 2- We replaced the word “restrictions” by “limitations” highlighted in red color in text (As your recommendations).
- 3- We omitted the line numbering method that obscuring the first word (As your recommendations).
- 4- We do our best to submit a clean version for our research paper, Hope that you find it good.

At the end, many thanks for your patience and very valuable recommendations.

Title : Adjuvant role of one hundred twenty eight multidetector computed tomography in categorizing adnexal masses

Authors: ElShaimaa Mohamed Mohamed,M.D^{a*}, Hend Ibrahim
Abdelrahim,Msc^a, Hamada Mohamed Khater,M.D^b, Amr Ahmed
Abdelrhman,M.D^c, Hanaa M. Ibrahim,M.D^d

^a Department of Radiodiagnosis, Faculty of Medicine, Zagazig University, Egypt.

^b Department of Radiodiagnosis, Faculty of Medicine, Banha University, Egypt.

^c Department of Obstetrics and Gynaecology, Faculty of Medicine, Zagazig University, Egypt.

^d Department of Pathology, Faculty of Medicine, Zagazig University, Egypt.

Correspondent:

Name: ElShaimaa Mohamed Mohamed,M.D.

Address: Department of Radiodiagnosis, Faculty of Medicine, Zagazig University,
Zagazig, Sharkia, 44519, Egypt.

Tel.:0020 1005515964.

E-mail address: bosy.radiology@gmail.com

Contributing authors:

- **ElShaimaa M. Mohamed, M.D:**

Address: Department of Radiodiagnosis, Faculty of Medicine, Zagazig University, Egypt.

Email: bosy.radiology@gmail.com

- **Hend Ibrahim AbdElrahim, Msc:**

Address: Department of Radiodiagnosis, Faculty of Medicine, Zagazig University, Egypt.

Email: Hendmido64@gmail.com

- **Hamada Mohamed Khater, M.D:**

Address: Department of radiodiagnosis, Faculty of Medicine, Banha University, Egypt.

Email: Drhamadakhater@gmail.com

- **Amr Ahmed Abdelrhman, M.D:**

Address: Department of Obstetrics and Gynaecology, Faculty of Medicine, Zagazig University, Egypt.

Email: Amrrobot@gmail.com

- **Hanaa M. Ibrahim, M.D:**

Address: Department of Pathology, Faculty of Medicine, Zagazig University, Egypt.

Email: Dr.hanaaghatwary@gmail.com

Acknowledgments

The authors show appreciation for all ⁵ staff members and colleagues of the Radiodiagnosis , Obstetrics and Gynaecology Departments, Zagazig University, for their helpful cooperation and all the study participants for their patience and support.

1
2
3
4
5
6
7
8
9
10
11
12
13
14
15
16
17
18
19
20
21
22
23
24
25
26
27
28
29
30
31
32
33
34
35
36
37
38
39
40
41
42
43
44
45
46
47
48
49
50
51
52
53
54
55
56
57
58
59
60
61
62
63
64
65

Adjuvant role of one hundred twenty eight multidetector computed tomography in categorizing adnexal masses.

Abstract: AIM: To assess the role of a 128-multidetector CT (MDCT) in discrimination between the benign and malignant adnexal masses.

PATIENTS AND METHODS: Retrospective review of the preoperative MDCT results of fifty women with clinically or sonographically diagnosed adnexal masses had been done by blinded radiologists to the surgical and histopathological outcomes. We excluded patient with bilateral ovarian masses, associated breast carcinoma with metastatic disease and postoperative patients. Our participants scanned by 128-row MDCT with its Maximum Intensity Projection (MIP), Multiplanar Reformatting (MPR) and Volume Rendering Imaging (VRI). Later, the outcome of MDCT compared with surgical and pathological results.

1 **RESULTS:** The mean age of patients was 52 years old. MDCT
2
3 diagnosed 23 (46%) benign masses and 27 (54%) malignant
4
5
6 masses. 128-row MDCT presented sensitivity, specificity and
7
8
9 diagnostic accuracy values 100%, 95.8% and 98% respectively
10
11
12 in discriminating malignant from benign adnexal masses
13
14
15 compared to histopathology. Our study revealed an excellent
16
17 agreement 1.0 between the MDCT and laparoscopy as a proof of
18
19 the origin of adnexal mass 100%.

20
21
22
23
24
25
26 **CONCLUSIONS:**

27
28 128-row MDCT provides a precise distinction of ovarian from
29
30 extraovarian pelvic masses and a dependable discrimination
31
32 between benign and malignant adnexal mass lesions. We
33
34 recommend recent advance 128-row MDCT as an excellent
35
36 reliable imaging technique to categorize adnexal masses.

37
38 **Keywords:** Adnexal masses; MDCT and ovarian neoplasms.

39
40
41
42 **INTRODUCTION**

43
44
45 Most of ovarian carcinomas remain clinically asymptomatic for
46
47 unlimited time, so two thirds of them at the time of first
48
49 detection have advanced to disease stage III or IV [1]. The
50
51
52
53
54
55
56
57
58
59
60
61
62
63
64
65

1 “silent” nature of ovarian malignancies and defective
2
3 population-based screening programs are the basic factors why
4
5
6 most of the females manifest with metastatic disease and late
7
8
9
10 problematical prognosis [2]. The precise characterization of
11
12
13 clinically picked up adnexal mass achieves by surgery and
14
15
16 histopathology [3]. Up to date imaging techniques establish
17
18
19 parallel accuracy as exploratory laparotomy [4]. The perfect
20
21
22 purpose of adnexal mass imaging is identifying the malignancy
23
24
25 [3] and discrimination the cases suitable for primary cyto-
26
27
28 reductive surgery and others needing neoadjuvant chemotherapy
29
30
31 preceding the surgery [5]. Ultrasonography (US) keeps on the
32
33
34 primary imaging tool in the diagnosis of a clinically suspected
35
36
37 adnexal mass, but it is incompetent in categorization of adnexal
38
39
40 lesions and in identifying the spread of disease in malignant
41
42
43 cases [4]. Recently developed advances in MDCT, which permit
44
45
46 thinner sections, faster imaging and good spatial resolution, has
47
48
49 recommended utilization in further classification of adnexal
50
51
52 mass and staging work-up of ovarian malignancy [6]. Now,
53
54
55 MDCT considers the gold standard imaging modality for staging
56
57
58
59
60
61
62
63
64
65

1 patients with ovarian carcinoma, detects tumor respectability
2
3 and assists in excellent treatment planning. This study in our
4
5
6 local population points to assess the advent of 128 slices MDCT
7
8
9 in identification and categorization of adnexal masses. The
10
11
12 histopathological and surgical results are our ideal standard for
13
14
15
16 comparison.
17

18 **Methods**

19 **Study design**

20
21
22
23 From Nov. 2016 to July 2017, we retrospectively reviewed the
24
25
26 preoperative MDCT data of fifty women with clinically or
27
28
29 sonographically picked up adnexal masses. Our radiological
30
31
32
33 observers (who had five experienced years in female imaging)
34
35
36
37 ignored with surgical and histopathological conclusions. We
38
39
40
41 excluded participant with bilateral ovarian masses, concurrent
42
43
44
45 breast carcinoma with metastatic disease and postoperative
46
47
48
49 cases. Institutional review board approval and a waiver of
50
51
52
53 informed consent received for the use of patient's data.
54
55
56
57
58
59
60
61
62
63
64
65

MDCT protocol

The present study carried out in our Radiodiagnosis department via a 128 MDCT scanner (PHILIPS Ingenuity 128). The cases positioned supine on the CT table. MDCT scan of abdomen and pelvis achieved from dome of the diaphragm to the symphysis pubis by 128 MDCT by a qualified technologist with five years' practice in MDCT scanning.

Image scanning parameters were as follows: detector collimation of 128x1mm, pitch 1.375, rotation time 0.75 second, table speed 15.4 mm/rotation, reconstruction interval 0.45 mm, 120 kV/300 mAs, acquisition time 9s. All scans achieved by a standard protocol using the triple phase. Precontrast scan of the upper abdomen; arterial phase by the Automatic Bolus Tracking System; portal phase generated by sixty seconds delay after the arterial one followed by MPR in axial, coronal and sagittal planes with five mm slice thickness of each. The non-ionic contrast medium omnipaque-300 had been given by a computer-controlled injector at rate of four ml/second through the antecubital vein of the right arm. Patients with malignant mass

1 suspicion had Gastrograffin oral contrast media before our
2
3 MDCT examination.
4

5
6 **Image analysis:**
7

8
9 The MDCT data processed at a workstation using Maximum
10 Intensity Projection (MIP), Multiplanar Reformat (MPR) and
11
12 Volume Rendering Images (VRI).
13
14
15

16
17
18 **Categorization of adnexal masses based upon MDCT data**
19
20 **interpretation:**
21

22
23 The imaging criteria involved the origin of the mass (ovarian or
24
25 extra-ovarian), lesion dimensions and content [3].
26
27

28
29 MDCT suggestive criteria ⁷ of benignity were the following: a
30
31 lesion diameter of less than four cm, completely cystic
32
33 components, a wall thickness of less than three mm and no
34
35 ascites or metastatic disease [7]. A unilocular or multilocular
36
37 cystic lesion filled with serous fluid of homogenous CT density
38
39 and unenhanced after contrast administration, well matched with
40
41
42
43
44
45
46
47
48
49
50
51 ¹ a serous cystadenoma. A multilocular cystic mass with thin
52
53
54
55
56
57
58
59
60
61
62
63
64
65
66
67
68
69
70
71
72
73
74
75
76
77
78
79
80
81
82
83
84
85
86
87
88
89
90
91
92
93
94
95
96
97
98
99
100
101
102
103
104
105
106
107
108
109
110
111
112
113
114
115
116
117
118
119
120
121
122
123
124
125
126
127
128
129
130
131
132
133
134
135
136
137
138
139
140
141
142
143
144
145
146
147
148
149
150
151
152
153
154
155
156
157
158
159
160
161
162
163
164
165
166
167
168
169
170
171
172
173
174
175
176
177
178
179
180
181
182
183
184
185
186
187
188
189
190
191
192
193
194
195
196
197
198
199
200
201
202
203
204
205
206
207
208
209
210
211
212
213
214
215
216
217
218
219
220
221
222
223
224
225
226
227
228
229
230
231
232
233
234
235
236
237
238
239
240
241
242
243
244
245
246
247
248
249
250
251
252
253
254
255
256
257
258
259
260
261
262
263
264
265
266
267
268
269
270
271
272
273
274
275
276
277
278
279
280
281
282
283
284
285
286
287
288
289
290
291
292
293
294
295
296
297
298
299
300
301
302
303
304
305
306
307
308
309
310
311
312
313
314
315
316
317
318
319
320
321
322
323
324
325
326
327
328
329
330
331
332
333
334
335
336
337
338
339
340
341
342
343
344
345
346
347
348
349
350
351
352
353
354
355
356
357
358
359
360
361
362
363
364
365
366
367
368
369
370
371
372
373
374
375
376
377
378
379
380
381
382
383
384
385
386
387
388
389
390
391
392
393
394
395
396
397
398
399
400
401
402
403
404
405
406
407
408
409
410
411
412
413
414
415
416
417
418
419
420
421
422
423
424
425
426
427
428
429
430
431
432
433
434
435
436
437
438
439
440
441
442
443
444
445
446
447
448
449
450
451
452
453
454
455
456
457
458
459
460
461
462
463
464
465
466
467
468
469
470
471
472
473
474
475
476
477
478
479
480
481
482
483
484
485
486
487
488
489
490
491
492
493
494
495
496
497
498
499
500
501
502
503
504
505
506
507
508
509
510
511
512
513
514
515
516
517
518
519
520
521
522
523
524
525
526
527
528
529
530
531
532
533
534
535
536
537
538
539
540
541
542
543
544
545
546
547
548
549
550
551
552
553
554
555
556
557
558
559
560
561
562
563
564
565
566
567
568
569
570
571
572
573
574
575
576
577
578
579
580
581
582
583
584
585
586
587
588
589
590
591
592
593
594
595
596
597
598
599
600
601
602
603
604
605
606
607
608
609
610
611
612
613
614
615
616
617
618
619
620
621
622
623
624
625
626
627
628
629
630
631
632
633
634
635
636
637
638
639
640
641
642
643
644
645
646
647
648
649
650
651
652
653
654
655
656
657
658
659
660
661
662
663
664
665
666
667
668
669
670
671
672
673
674
675
676
677
678
679
680
681
682
683
684
685
686
687
688
689
690
691
692
693
694
695
696
697
698
699
700
701
702
703
704
705
706
707
708
709
710
711
712
713
714
715
716
717
718
719
720
721
722
723
724
725
726
727
728
729
730
731
732
733
734
735
736
737
738
739
740
741
742
743
744
745
746
747
748
749
750
751
752
753
754
755
756
757
758
759
760
761
762
763
764
765
766
767
768
769
770
771
772
773
774
775
776
777
778
779
780
781
782
783
784
785
786
787
788
789
790
791
792
793
794
795
796
797
798
799
800
801
802
803
804
805
806
807
808
809
810
811
812
813
814
815
816
817
818
819
820
821
822
823
824
825
826
827
828
829
830
831
832
833
834
835
836
837
838
839
840
841
842
843
844
845
846
847
848
849
850
851
852
853
854
855
856
857
858
859
860
861
862
863
864
865
866
867
868
869
870
871
872
873
874
875
876
877
878
879
880
881
882
883
884
885
886
887
888
889
890
891
892
893
894
895
896
897
898
899
900
901
902
903
904
905
906
907
908
909
910
911
912
913
914
915
916
917
918
919
920
921
922
923
924
925
926
927
928
929
930
931
932
933
934
935
936
937
938
939
940
941
942
943
944
945
946
947
948
949
950
951
952
953
954
955
956
957
958
959
960
961
962
963
964
965
966
967
968
969
970
971
972
973
974
975
976
977
978
979
980
981
982
983
984
985
986
987
988
989
990
991
992
993
994
995
996
997
998
999
1000

1 **cystadenoma**. An oblong, tubular, fluid filled adnexal lesion
2
3 was well matched with **hydro or pyosalpinx** diagnosis [8]. Fat
4
5 density within adnexal cyst, with or without calcification, was
6
7 characteristic of **dermoid cyst** [9] (Fig.1). The finding of a
8
9 sharply demarcated, homogenous hyperdense solid ovarian mass
10
11 (about 50-70HU), was compatible with a benign ovarian lesion
12
13 with hemorrhagic content (**hemorrhagic cyst or Chocolate**
14
15 **cyst**) (Fig.2). On the contrary, MDCT primary criteria
16
17 suggestive for malignancy were the following: size greater than
18
19 four cm, ¹ a mass mixed cystic and solid, with solid portions
20
21 enhancing after contrast use and necrosis in a solid tumor [7,
22
23 10]. In the characterization of an adnexal mass, the enhancement
24
25 of the wall or septa was of a great interest. Secondary criteria
26
27 such as, pelvic organ or pelvic sidewall involvement, ascites,
28
29 peritoneal metastases and lymphadenopathy established the
30
31 malignancy outcome. An adnexal mass categorized as malignant
32
33 when at least two primary criteria or one primary and one
34
35 secondary criterion achieved [7] (Fig.3, 4).
36
37
38
39
40
41
42
43
44
45
46
47
48
49
50
51
52
53
54
55
56
57
58
59
60
61
62
63
64
65

Surgical and Pathological assessment:

1
2
3 A skillful gynecologist gave detailed surgical data and
4
5
6 illustrated pelvis, lymph nodes and peritoneum metastatic
7
8
9 occurrence. A well qualified pathologist analyzed all the
10
11
12 excision samples without any awareness of the MDCT or
13
14
15 surgical outcomes. The surgical and histopathological data was
16
17
18 the ideal control standard in the assessment of MDCT adjuvant
19
20
21 role in characterization of adnexal mass.
22
23
24

Statistical analysis

25
26
27 Data verified, inserted and analyzed via Microsoft Excel
28
29
30 software. Data introduced to statistical Package for the social
31
32
33 sciences (SPSS version 20.0) software for analysis. Results
34
35
36 offered as mean \pm standard deviation (SD). The sensitivity,
37
38
39 specificity and diagnostic accuracy values for MDCT calculated
40
41
42 in comparison with surgical and histopathological results.
43
44
45

46
47
48 Cohen's kappa coefficient is a statistic which calculates inter-
49
50
51 rater agreement for qualitative (categorical) items. It verifies the
52
53
54 agreement between MDCT results and two controls (surgery and
55
56
57
58
59
60
61
62
63
64
65

1 histopathology) results of adnexal masses. P value was set at >
2
3 0.05 for significant results & > 0.001 for high significant result.
4
5

6 **Results**

7
8
9
10 Fifty women with clinically or sonographically picked up
11
12 adnexal mass who performed preoperative MDCT during the
13
14 study period enrolled in our work. Age of our participants was
15
16 ranging from 34 to 70 years old with mean age equals 52 years
17
18 old. The pelvic pain and congestion (76% and 30%) were the
19
20 commonest complaints while the least common complaints were
21
22 fever and persistent fatigue (6% and 4%).
23
24
25
26
27
28
29
30

31
32 **(Table 1)** demonstrates the most common MDCT findings
33
34 according to the origin was ovarian origin (86%) with malignant
35
36 frequency about 55.8% for cystic lesion and 7% for solid
37
38 lesions. Tubal lesions were the least common origin (6%) and
39
40 other lesions as subserous fibroid and appendicular abscess were
41
42 (8%).
43
44
45
46
47
48
49
50

51
52 **(Table 2)** represents the histopathology and laparoscopic
53
54 findings among our participants with most common malignant
55
56 ovarian tumors are serous cystadenocarcinoma (51.9 %) and
57
58
59
60
61
62
63
64
65

1 least common is granulosa cell tumor (3.7%). While among the
2
3 benign ovarian tumors, the cystadenoma is the most common
4
5
6 and the least is ovarian fibroma.
7
8
9

10 On our study, cases that diagnosed by histopathology are in
11
12 agreement with that assessed by MDCT excluding only one
13
14 false positive case of cystadenoma that diagnosed as malignant
15
16 cystic lesion by MDCT . Most undifferentiated lesions by
17
18 MDCT were benign lesions by histopathology. So agreement is
19
20 good 0.75 between MDCT and histopathology (**Table 3**).
21
22
23
24
25
26
27
28
29

30
31 (**Table 4**) illustrates the excellent agreement between the MDCT
32
33 findings and laparoscopic results as a confirmation of the
34
35 adnexal mass origin 100% in our work.
36
37
38
39

40 (**Table 5**) demonstrates sensitivity, specificity and diagnostic
41
42 accuracy of 128 MDCT in differentiating malignant from benign
43
44 adnexal masses compared to histopathology.
45
46
47
48
49

50 **Discussion**

51
52
53
54 Differentiation between benign and malignant adnexal masses
55
56 clinically is tricky and depends essentially on imaging outcome.
57
58
59
60
61
62
63
64
65

1 Ultrasonography evaluates the morphological and Doppler
2 criteria of the adnexal mass [10]. Yet, the reported accuracy of
3 US in categorizing the ¹ adnexal masses differs from 65–94% for
4 gray-scale US, 35–88% for color Doppler flow imaging, and
5 48–99% for Doppler arterial resistance measurements [3]. The
6 well qualified skillful sonographer, the patient's menopausal
7 status and absent exclusive sonographic diagnostic criteria are
8 the principal obstacles in front of US in discriminating adnexal
9 malignancies [11].

10 The innovation of 128-row CT scanner enhances ⁴ the sensitivity
11 of CT in identifying and categorizing adnexal masses. MDCT
12 scanners have obviously amplified volume coverage, together
13 with reduced scanning time to less than one min in most cases
14 [12, 13]. Our 128 MDCT scanner enhances temporal resolution
15 and diminishes significantly the motion artifacts. An additional
16 technical improvement is the acquisition of thin slices (section
17 collimation of 0.9 mm). All above-mentioned benefits produce
18 ¹ possible isotropic imaging, permitting the reformation of images
19 at any plane with spatial resolution identical to the initial

1 scanning plane. 128-row CT scanners let an inclusive
2
3 assessment of the whole abdomen, with few seconds scan
4
5 duration on the average, using a slice thickness of less than one
6
7 mm, avoiding excessive patient radiation exposure.
8
9

10 Identification of the pelvic mass origin is challenging, as ovarian
11
12 and extra-ovarian masses may have equivalent morphological
13
14 criteria. Our applied CT protocol together with MPR allowed a
15
16 sure detection of the ovaries and an exact differentiation
17
18 between ovarian and extra-ovarian pelvic masses [14].
19

20 Our present study established 100% sensitivity, 95.8%
21
22 specificity and 98% diagnostic accuracy in differentiating
23
24 benign from malignant adnexal masses. Our result is amazing in
25
26 comparison to the previous studies. Kinkel et al. [15] in their
27
28 meta-analysis stated a sensitivity and specificity of 81% and
29
30 87% respectively. ² Tsili et al. [3] described the sensitivity of the
31
32 16-slice MDCT to be 90 % and accuracy of 89.1% for detecting
33
34 malignant tumors in patients with an adnexal mass. Conversely,
35
36 higher sensitivity (90.5%) , specificity (93.7%)and accuracy
37
38 (92.9%) had been stated by the same author in the study
39
40
41
42
43
44
45
46
47
48
49
50
51
52
53
54
55
56
57
58
59
60
61
62
63
64
65

1 achieved for comparing MDCT and MRI diagnostic
2 performances in characterizing and differentiating ovarian
3 masses” the difference was not proved statistically
4 significant”[16]. Gatreh-Samani et al. [17] mentioned results
5 (92.8% sensitivity, 88% specificity and 91.5 % accuracy) in
6 their study might be as a result of thinner slices of 64-row
7 MDCT which improved by reconstructed images. Enhanced
8 results reported by Mubarak et al. [4] as a sensitivity, specificity
9 and accuracy of 97%, 96% and 98% respectively. Also, Khattak
10 et al. [2] stated a diagnostic accuracy of 90.5 and 96 respectively
11 by reader A and B.
12
13
14
15
16
17
18
19
20
21
22
23
24
25
26
27
28
29
30
31
32
33
34

35 Our reasonable result achieved by new innovation 128 MDCT
36 which produces a precise assessment of the internal architecture
37 of the adnexal masses and picks up the secondary criteria.
38
39
40
41
42
43

44 ¹ Single-detector row CT scanners stated a sensitivity of 85–93%
45 for the discovery of peritoneal metastases, but the sensitivity
46 severely diminished to 25–50% for metastatic implants of one
47 cm or lesser in dimensions [18]. MDCT progressed the
48 ⁶ sensitivity of CT in diagnosing peritoneal carcinomatosis, owing
49
50
51
52
53
54
55
56
57
58
59
60
61
62
63
64
65

1 to the acquisition of thin slices and the high quality MPRs, for
2 these reasons picking up the sub-centimeter implants [19, 20]. In
3 our work, 128 MDCT recognized all cases of peritoneal
4 carcinomatosis in patients with ovarian malignancies. One case
5 showed peritoneal lesions ranging from 0.7 to 2 cm in diameter,
6 all detected on MDCT. The other one 0.5 cm detected at
7 Douglas pouch.
8

9
10
11
12
13
14
15
16
17
18
19
20
21
22
23
24
25
26
27
28
29
30
31
32
33
34
35
36
37
38
39
40
41
42
43
44
45
46
47
48
49
50
51
52
53
54
55
56
57
58
59
60
61
62
63
64
65

Three cases of undifferentiated and mixed ovarian lesions that later diagnosed by histopathology as benign lesions. Tubal origin lesions were three from the total 50 cases, two of them were tubo-ovarian abscesses (**Fig.5**) and the other was hydrosalpinx. Other adnexal lesions were appendicular mass with fecolith and subserous fibroids (8%) of cases. Yitta et al. [21] mentioned that MPR images may be beneficial in recognizing a tubo-ovarian abscess from acute appendicitis, either of which imitating a pyosalpinx.

Our study shows excellent agreement 1.0 between the 128-row MDCT and surgical laparoscopy as confirming the origin of adnexal mass 100% and agreement is good 0.75 between 128-

1 row MDCT and histopathology. Gatreh-Samani et al. [17]
2
3 discovered significant agreements between 64-row MDCT and
4
5
6 surgical outcomes (Kappa = 0.891) and between 64-row MDCT
7
8
9 and histopathological findings (K= 0.858).
10
11

12 **Possible Limitations in our study:**

13
14
15
16
17 **Firstly**, a difficulty in exact defining whether a large adnexal
18 mass was unilateral or bilateral. This problem occurs whether
19
20 MDCT or other imaging technique used. **Secondly**, in our study
21 the papillary projections lead to the false-positive diagnosis in
22
23 patient with multicystic ovarian tumor, which proved a
24
25 cystadenoma on histopathology. **Thirdly**, the relative small
26
27 number of cases (50 cases only) involved in our sample and
28
29 retrospective design study producing selection, verification
30
31 biases and high sensitivity up to 100%. So we recommended
32
33 increasing the number of cases in future studies. **Fourthly**, in
34
35 MDCT images assessment (as, we had more than one observer
36
37 radiologist), the inter-observer reliability was not statistically
38
39 performed. **Fifthly**, the use of the risk of Malignancy index
40
41 using USS and Ca125 is not performed.
42
43
44
45
46
47
48
49
50
51
52
53
54
55
56
57
58
59
60
61
62
63
64
65

1
2
3
4
5
6
7
8
9
10
11
12
13
14
15
16
17
18
19
20
21
22
23
24
25
26
27
28
29
30
31
32
33
34
35
36
37
38
39
40
41
42
43
44
45
46
47
48
49
50
51
52
53
54
55
56
57
58
59
60
61
62
63
64
65

CONCLUSIONS:

128-row MDCT provides a precise distinction of ovarian from extraovarian pelvic masses and a dependable discrimination between benign and malignant adnexal mass lesions. We recommend recent advance 128-row MDCT as an excellent reliable imaging technique to categorize adnexal masses.

References

1. Kombächer P, Hamm B, Becker R, Hese S, Weitzel HK, Wolf KJ. Tumors of the adnexa--a comparison of magnetic resonance tomography, endosonography and the histological findings. RoFo: Fortschritte auf dem Gebiete der Rontgenstrahlen und der Nuklearmedizin 1992; 156(4):303-8.
2. Khattak YJ, Hafeez S, Alam T, Beg M, Awais M, Masroor I. Ovarian masses: Is multi-detector computed tomography a reliable imaging modality. Asian Pac J Cancer Prev 2013; 14(4):2627-30.
3. Tsili AC, Tsampoulas C, Charisiadi A, Kalef-Ezra J, Dousias V, Paraskevaidis E, et al. Adnexal masses: accuracy of detection

1 and differentiation with multidetector computed
2 tomography. *Gynecologic oncology* 2008; 110(1):22-31.
3
4

5
6
7 4. Mubarak F, Alam MS, Akhtar W, Hafeez S, Nizamuddin N.
8

9
10 Role of multidetector computed tomography (MDCT) in
11 patients with ovarian masses. *International journal of*
12 *women's health* 2011; 3:123.
13
14

15
16
17 5. Sahdev A. CT in ovarian cancer staging: how to review and
18 report with emphasis on abdominal and pelvic disease for
19 surgical planning. *Cancer Imaging* 2016; 16(1):19.
20
21

22
23
24 6. Jung SI, Park HS, Kim YJ, Jeon HJ. Multidetector computed
25 tomography for the assessment of adnexal mass: is
26 unenhanced CT scan necessary? *Korean journal of radiology*
27 2014; 15(1):72-9.
28
29

30
31 7. Jung SE, Lee JM, Rha SE, Byun JY, Jung JI, Hahn ST. CT and
32 MR imaging of ovarian tumors with emphasis on differential
33 diagnosis. *Radiographics* 2002; 22(6):1305-25.
34
35
36
37
38
39
40
41
42
43
44
45
46
47
48
49
50
51
52
53
54
55
56
57
58
59
60
61
62
63
64
65

1
2
3
4
5
6
7
8
9
10
11
12
13
14
15
16
17
18
19
20
21
22
23
24
25
26
27
28
29
30
31
32
33
34
35
36
37
38
39
40
41
42
43
44
45
46
47
48
49
50
51
52
53
54
55
56
57
58
59
60
61
62
63
64
65

8. Outwater EK, Siegelman ES, Chiowanich P, Kilger AM, Dunton CJ, Talerman A. Dilated fallopian tubes: MR imaging characteristics. *Radiology* 1998; 208(2):463-9.
9. Outwater EK, Siegelman ES, Hunt JL. Ovarian teratomas: tumor types and imaging characteristics. *Radiographics* 2001; 21(2):475-90.
10. Imaoka I, Wada A, Kaji Y, Hayashi T, Hayashi M, Matsuo M, et al. Developing an MR imaging strategy for diagnosis of ovarian masses. *Radiographics* 2006; 26(5):1431-48.
11. Jeong YY, Outwater EK, Kang HK. Imaging evaluation of ovarian masses. *Radiographics* 2000; 20(5):1445-70.
12. Flohr TG, Schaller S, Stierstorfer K, Bruder H, Ohnesorge BM, Schoepf UJ. Multi-detector row CT systems and image-reconstruction techniques. *Radiology* 2005; 235(3):756-73.
13. Kohl G. The evolution and state-of-the-art principles of multislice computed tomography. *Proceedings of the American thoracic Society* 2005; 2(6):470-6.

1
2
3
4
5
6
7
8
9
10
11
12
13
14
15
16
17
18
19
20
21
22
23
24
25
26
27
28
29
30
31
32
33
34
35
36
37
38
39
40
41
42
43
44
45
46
47
48
49
50
51
52
53
54
55
56
57
58
59
60
61
62
63
64
65

14. Murase E, Siegelman ES, Outwater EK, Perez-Jaffe LA, Tureck RW. Uterine leiomyomas: histopathologic features, MR imaging findings, differential diagnosis, and treatment. *Radiographics* 1999; 19(5):1179-97.
15. Kinkel K, Lu Y, Mehdizade A, Pelte MF, Hricak H. Indeterminate ovarian mass at US: incremental value of second imaging test for characterization—meta-analysis and Bayesian analysis. *Radiology* 2005; 236(1):85-94.
16. Tsili AC, Tsampoulas C, Argyropoulou M, Navrozoglou I, Alamanos Y, Paraskevaidis E, et al. Comparative evaluation of multidetector CT and MR imaging in the differentiation of adnexal masses. *European radiology* 2008; 18(5):1049-57.
17. Gatreh-Samani F, Tarzamni MK, Olad-Sahebmadarek E, Dastranj A, Afrough A. Accuracy of 64-multidetector computed tomography in diagnosis of adnexal tumors. *Journal of ovarian research* 2011; 4(1):15.
18. Coakley FV, Choi PH, Gougoutas CA, Pothuri B, Venkatraman E, Chi D, et al. Peritoneal metastases: detection with spiral

1 CT in patients with ovarian cancer. Radiology 2002;
2
3 223(2):495-9.
4
5

6
7 19. Pannu HK, Horton KM, Fishman EK. Thin section dual-phase
8 multidetector-row computed tomography detection of
9
10 peritoneal metastases in gynecologic cancers. Journal of
11
12 computer assisted tomography 2003; 27(3):333-40.
13
14
15

16
17 20. Pannu HK, Bristow RE, Montz FJ, Fishman EK. Multidetector
18
19 CT of peritoneal carcinomatosis from ovarian cancer.
20
21 Radiographics 2003; 23(3):687-701.]
22
23
24

25
26 21. Yitta S, Hecht EM, Slywotzky CM, Bennett GL. Added value
27
28 of multiplanar reformation in the multidetector CT
29
30 evaluation of the female pelvis: a pictorial review.
31
32 Radiographics 2009; 29(7):1987-2003.
33
34
35
36
37
38
39
40
41
42
43

44
45 **The figure legends**
46

47
48 **Figure 1: (A&B)** Axial images postcontrast show LT. ovarian
49
50 cyst thin walled and clear content, with calcification inside
51
52 (Yellow arrow) and papillary projections (Black arrow). **(C&D)**
53
54
55
56
57
58 Sagittal images postcontrast show the actual size of the cyst 14
59
60
61
62
63
64
65

1 cm x 20x6 cm, and the intracystic calcification. **(E&F)** Coronal
2
3 images show the thickness of the papillary projection about 13
4
5 mm and the calcification inside. Histopathological examination
6
7 reveals **dermoid cyst**.
8
9

10
11
12
13 **Figure 2: (A)** Postcontrast Axial MDCT image shows RT.
14
15 ovarian complicated cyst (Yellow arrow) just posterior to the
16
17 RT iliac vessels measuring 42 mm x 37 mm with thickened
18
19 mildly enhanced wall. **(B)** Sagittal reconstructed image shows
20
21 the exact size of the ovarian cyst (Yellow arrow). **(C)** Another
22
23 sagittal image shows the normal sized uterus with hypodense
24
25 endometrium. **(D)** Coronal reconstructed image reveals the
26
27 slight high density fluid content of ovarian cyst in comparison to
28
29 the clear urine in UB and left ovary not seen. Histopathological
30
31 examination after laparoscopy reveals **chocolate cyst**
32
33 "**endometrioma**".
34
35
36
37
38
39
40
41
42
43
44
45
46
47
48
49

50
51 **Figure 3: (A&B)** Axial images show the huge pelviabdominal
52
53 mass of mixed density and large mural soft tissue density...
54
55 Uterus seen well defined homogenous with regular hypodense
56
57 endometrial line (blue arrow). The lesion is mostly RT.adnexal
58
59
60
61
62
63
64
65

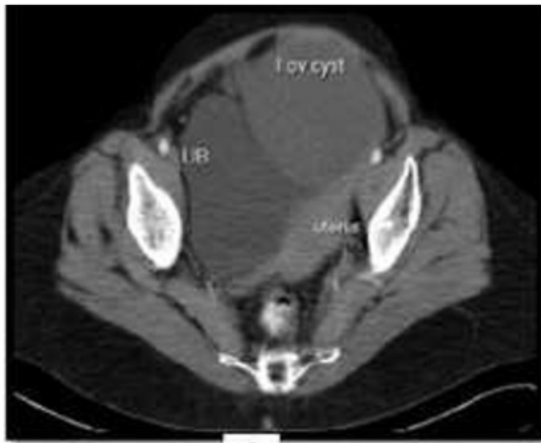1 in origin. (C) Coronal image shows huge pelviabdominal mass
2
3 mainly pelvic and midline. (D) Sagittal image shows the mass
4
5 seen occupying the whole pelvis and extending abdominal till
6
7 the liver, with prominent thick septations (Yellow arrows) more
8
9 than 6 mm. Histopathological study reveals **mucinous**
10
11
12
13
14
15
16 **cystadenocarcinoma.**

17
18
19
20 **Figure 4: (A&B)** Axial images show the enlarged RT ovary 12
21
22 x 14 cm with central areas of breakdown (blue star). **(C&D)**
23
24 Axial images show prominent abnormal feeding artery (blue
25
26 arrow) and normal left ovary (Yellow arrow) among the
27
28 moderate ascites. **(E)** Sagittal image shows the uterus with
29
30 thickened hypodense endometrium (Black arrow) measuring
31
32 40mm >associated endometrial hyperplasia. **(F)** Axial cut
33
34 postcontrast shows abnormal invasion of the base of UB (Red
35
36 arrow) mostly metastasis. Postoperative histopathology reveals
37
38
39
40
41
42
43
44
45
46
47
48
49 **granulosa cell tumor juvenile type.**

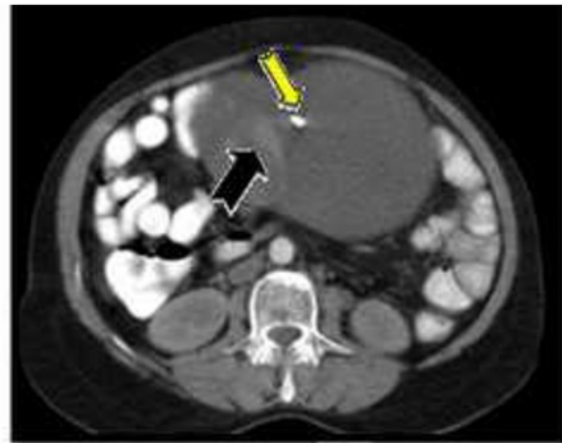
50
51
52
53 **Figure 5: (A&B)** Axial post contrast images show the actual
54
55 size of the mass 50 mm x48 mm just right to the normal uterus.
56
57
58
59
60
61
62
63
64
65

1 RT ovary seen continuous with the RT fallopian tube (Red
2
3 arrow) which is cystic, elongated with thickened wall and
4
5
6 internal septations with hazy surrounding fat planes denoting
7
8
9
10 tubo-ovarian abscess. (C) Coronal image shows the lesion
11
12
13 "complex- fluid collection" (Red arrow) and the normal uterus.
14
15
16 (D) Sagittal image reveals the lesion (Red arrow).
17
18
19
20
21
22
23
24
25
26
27
28
29
30
31
32
33
34
35
36
37
38
39
40
41
42
43
44
45
46
47
48
49
50
51
52
53
54
55
56
57
58
59
60
61
62
63
64
65

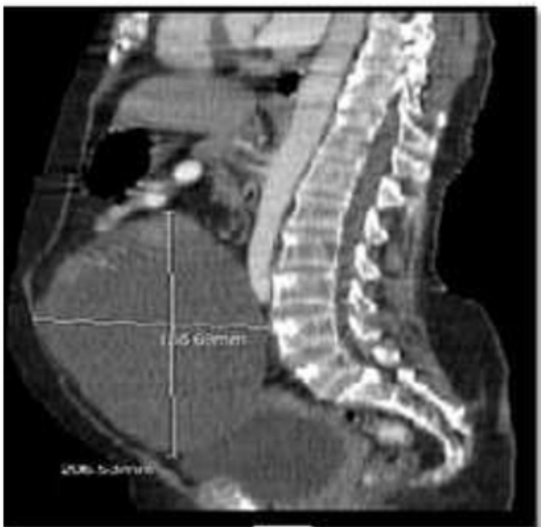Histopathological examination reveals thick fibrous cystic wall
and heavy inflammatory cellular infiltrate... picture of **tubo-
ovarian abscess.**



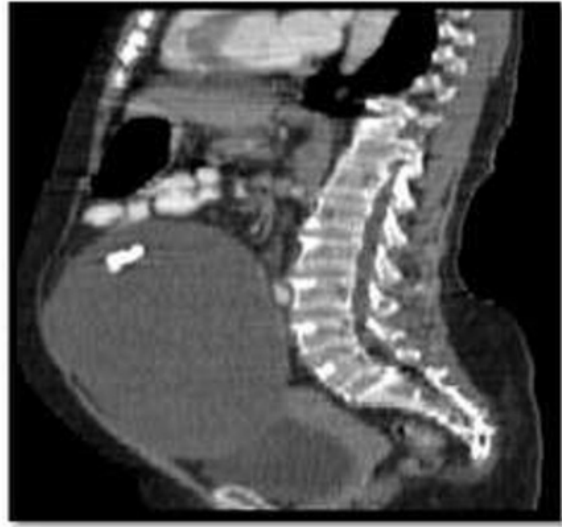A



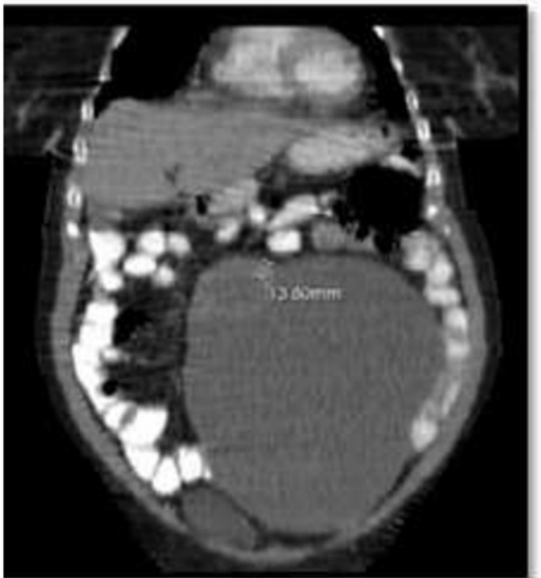
B



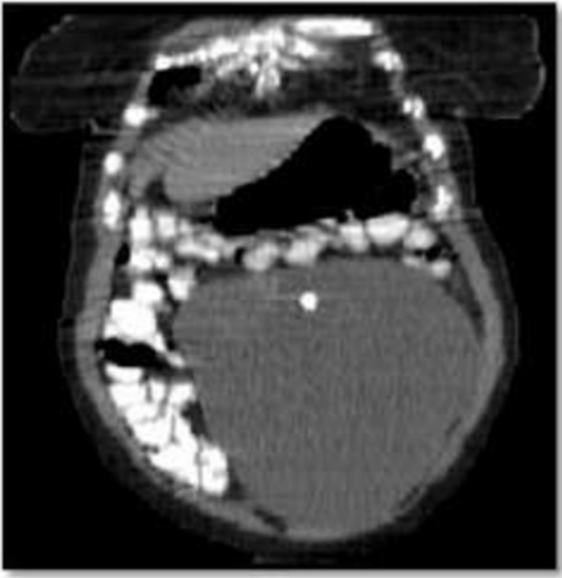C



D

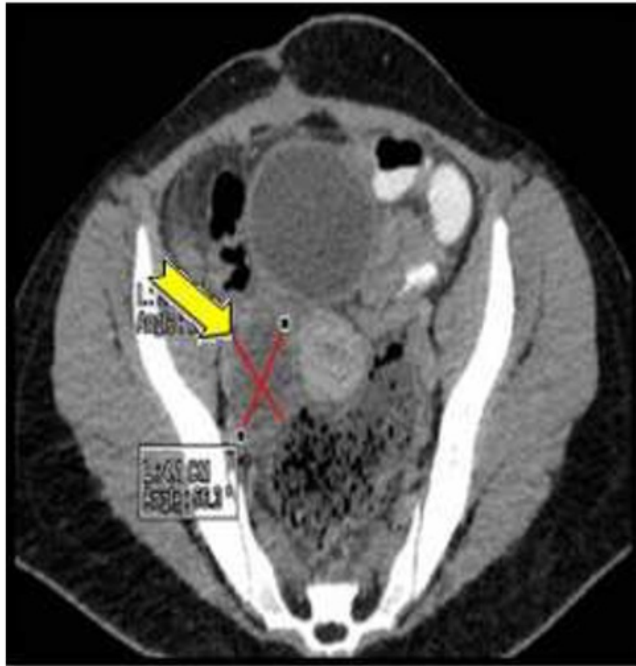

E

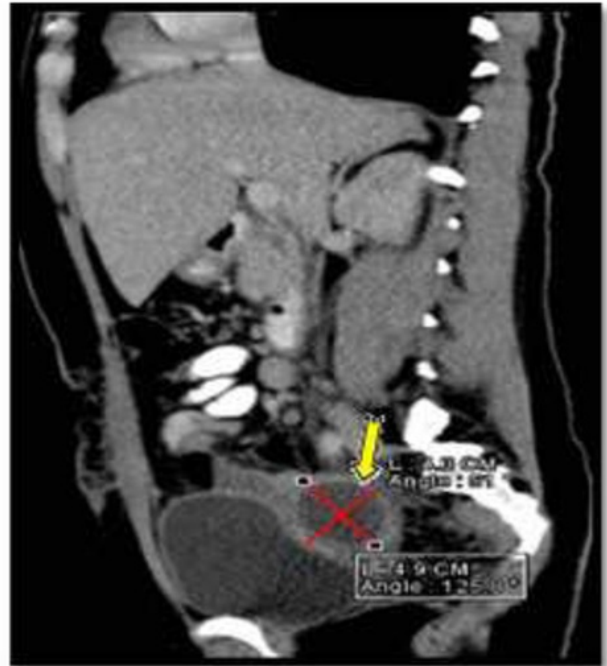

F

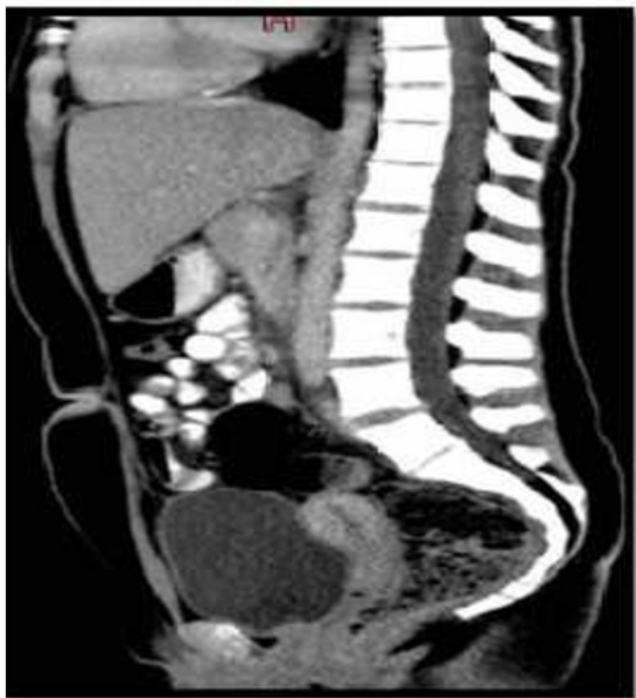Figure
[Click here to download high resolution image](#)



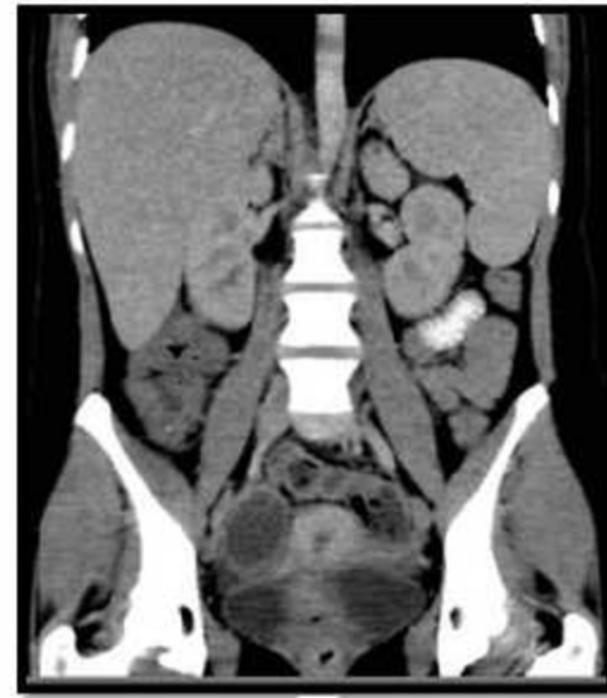
A



B

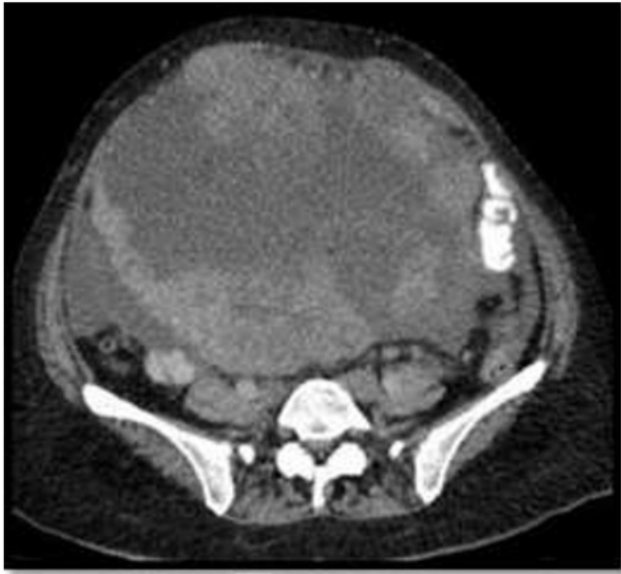

C

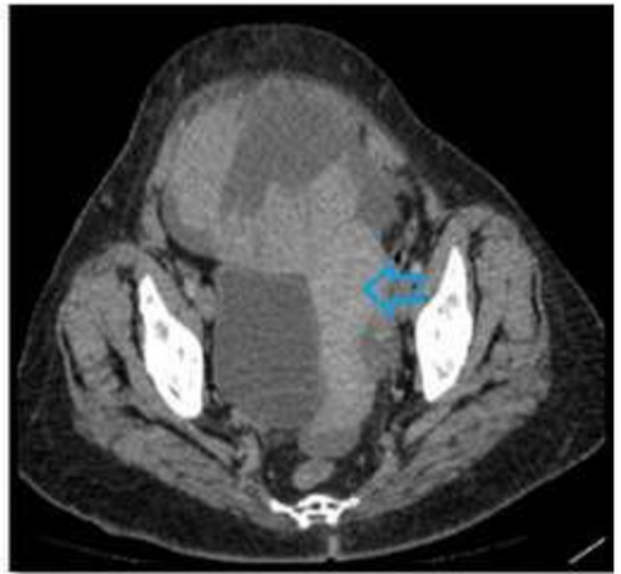


D

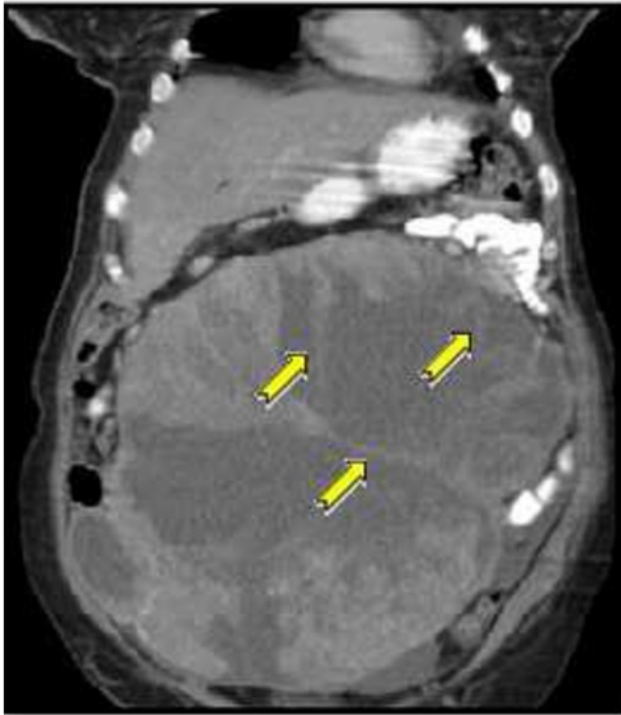
Figure
[Click here to download high resolution image](#)



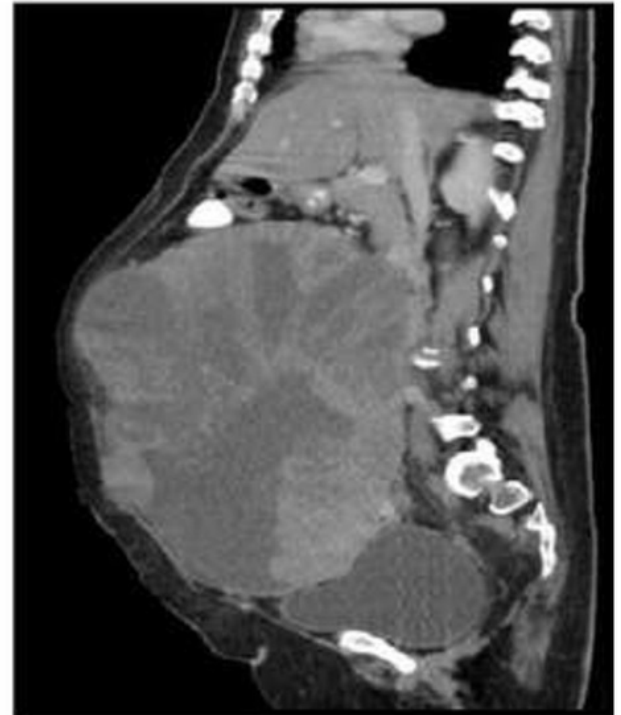A



B

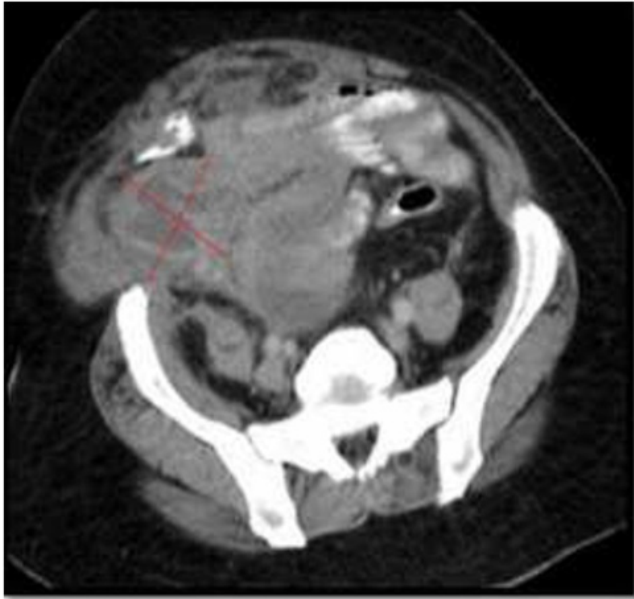


C

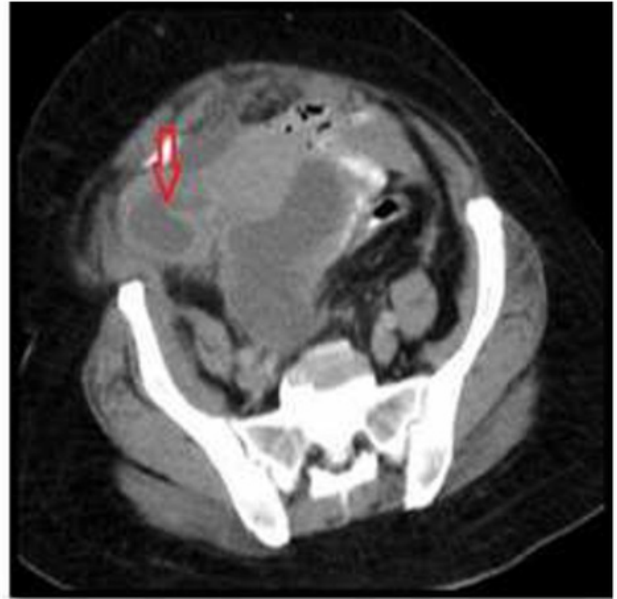

D

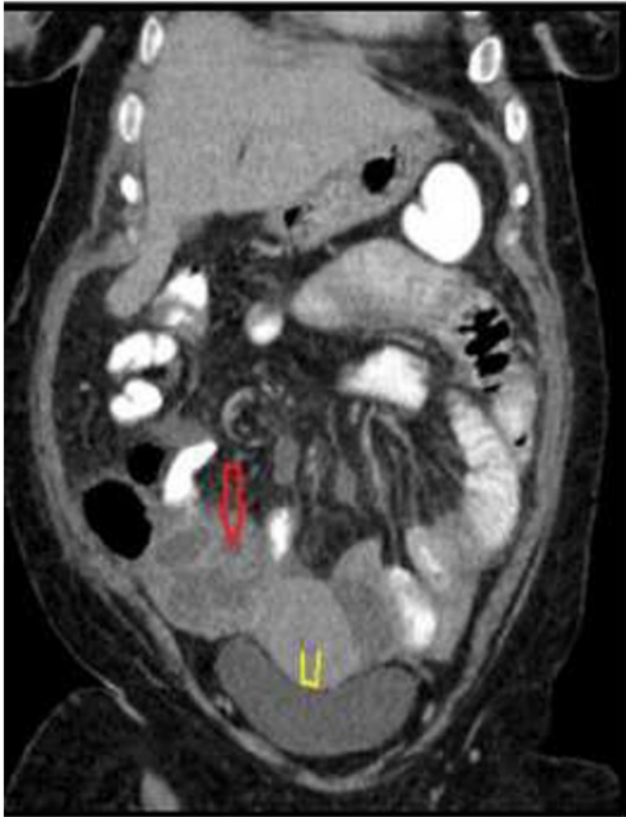
Figure
[Click here to download high resolution image](#)



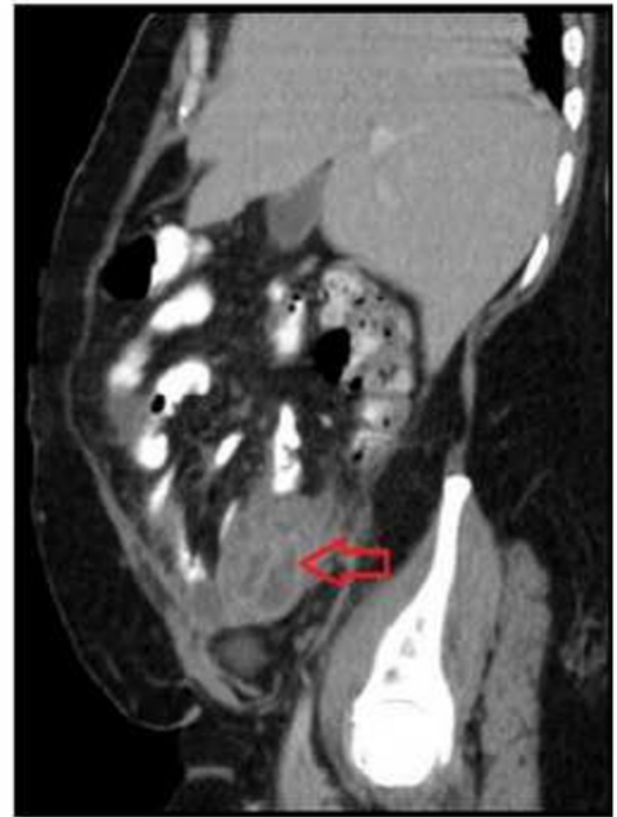
A



B

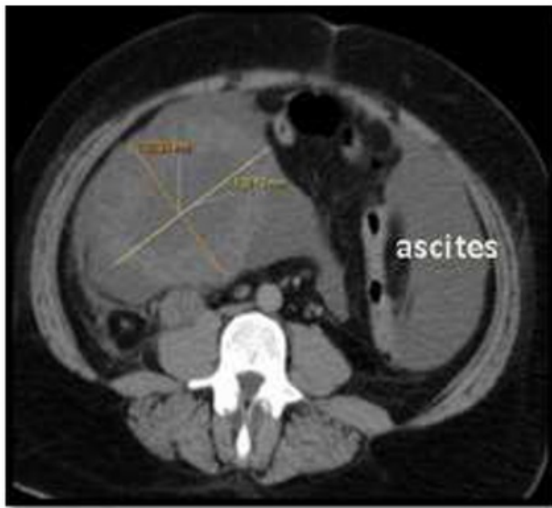

C

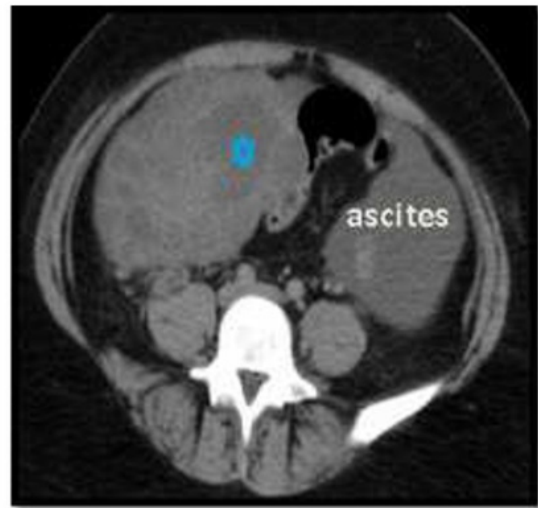


D

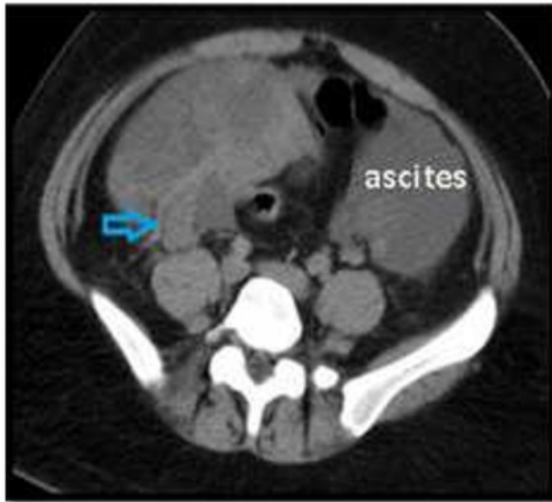Figure
[Click here to download high resolution image](#)



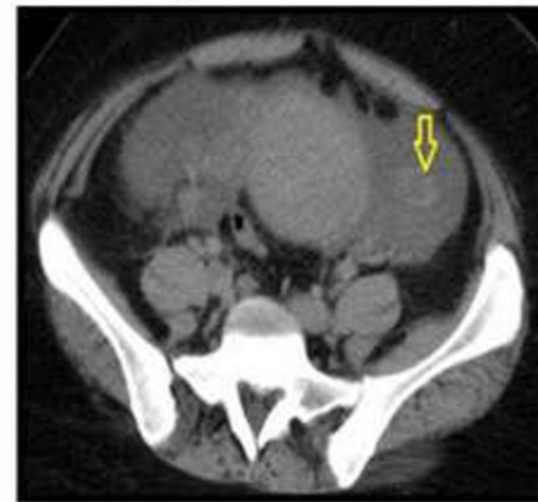
A



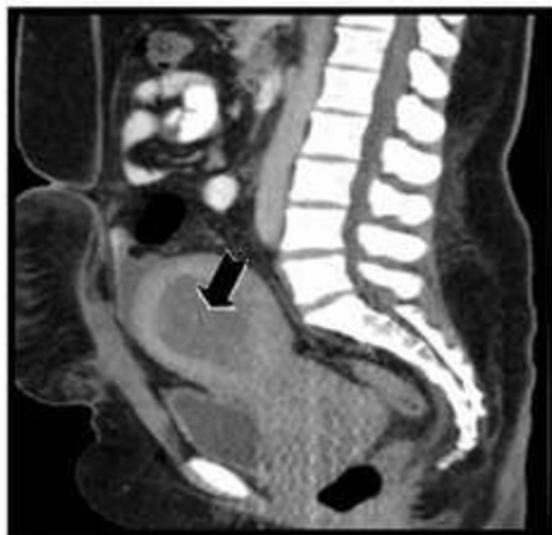B



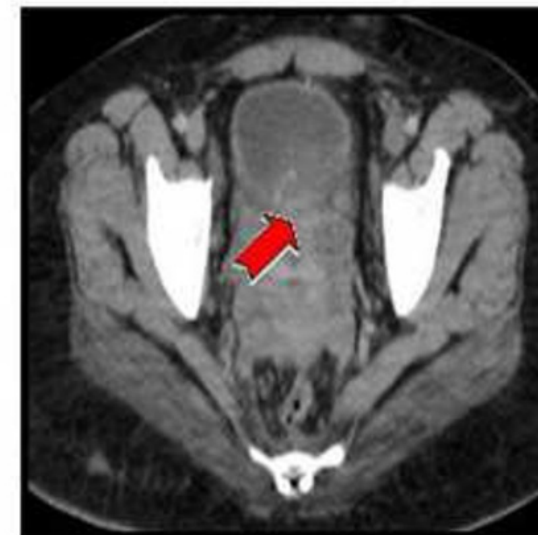
C



D



E



F

Table (1): MDCT Findings in study participants:

Origin	MDCT Findings	No.	%
Ovarian (n=43)	▪ <i>Malignant ovarian cyst ± ascitis</i>	24	55.8
	▪ <i>Malignant solid ovarian lesion ± hemorrhage</i>	3	7.0
	▪ <i>Benign ovarian cyst</i>	3	7.0
	▪ <i>Benign ovarian cyst with fat & calcification</i>	3	7.0
	▪ <i>Complicated ovarian cyst</i>	3	7.0
	▪ <i>Simple cyst</i>	3	7.0
	▪ <i>Undifferentiated ovarian cyst</i>	2	4.7
	▪ <i>Ovarian benign mixed lesion</i>	1	2.3
	▪ <i>Benign ovarian solid lesion</i>	1	2.3
Tubal (n=3)	▪ <i>Tubo-ovarian abscess</i>	2	66.7
	▪ <i>Hydrosalpinx</i>	1	33.3
Other (n=4)	▪ <i>Sub serous fibroid</i>	3	75.0
	▪ <i>Appendicular mass & fecolith</i>	1	25.0

Table (2): Histopathology and laparoscopy Findings in study participants:

Origin	Histopathology and laparoscopy Findings	No.	%
Ovarian (n=43)	▪ Benign (n=16):		
	<i>Cystadenoma</i>	5	31.3
	<i>Dermoid cyst</i>	3	18.8
	<i>Chocolate cyst</i>	3	18.8
	<i>Simple cyst</i>	2	12.5
	<i>Complicated benign ovarian cyst</i>	2	12.5
	<i>Fibroma</i>	1	6.3
	▪ Malignant (n=27):		
	<i>Serous cyst adenocarcinoma</i>	14	51.9
	<i>Mucinous cyst adenocarcinoma</i>	11	40.7
Tubal (n=3)	<i>Malignant germ cell tumor</i>	1	3.7
	<i>Granulosa cell tumor</i>	1	3.7
	▪ Benign (n=3):		
Other (n=4)	<i>Tubo-ovarian abscess</i>	2	66.7
	<i>Hydrosalpinx</i>	1	33.3
	▪ Benign (n=3):		
	<i>Subserous fibroid</i>	2	50.0
	<i>Appendicitis</i>	1	25.0
	▪ Malignant (n=1):		
	<i>Leiomyosarcoma of subserous fibroid</i>	1	25.0

Table (3): Agreement between MDCT and histopathology:

MDCT	Histopathology				K	P
	Malignant		Benign			
Malignant	26	96.3%	1	4.3%	0.75#	0.000**
Benign	0	0.0%	17	73.9%		
Undifferentiated	1	3.7%	5	21.7%		
Total	27	100%	23	100%		

Good agreement** High statistical significance

Table (4): Agreement between MDCT and laparoscopy:

MDCT	Laparoscopy						K	P
	Ovarian		Tubal		Other			
Ovarian	43	100%	0	0.0%	0	0.0%	1.0#	0.000**
Tubal	0	0.0%	3	100%	0	0.0%		
Other	0	0.0%	0	0.0%	4	100%		
Total	27	100%	3	100%	23	100%		

Excellent agreement** High statistical significance

Table (5): Sensitivity, specificity and diagnostic accuracy of 128 MDCT in differentiating malignant from benign adnexal masses compared to histopathology:

Sensitivity (%) ^a	Specificity (%) ^b	DA (%) ^d
100%	95.8%	98%

3-Adjuvant role of one hundred twenty eight multidetector computed tomography in categorizing adnexal masses

ORIGINALITY REPORT

7%

SIMILARITY INDEX

PRIMARY SOURCES

- 1 [A.C. Tsili, C. Tsampoulas, A. Charisiadi, John Kalef-Ezra, V. Dousias, E. Paraskevaidis, S.C. Efremidis. "Adnexal masses: Accuracy of detection and differentiation with multidetector computed tomography", Gynecologic Oncology, 2008](#) 102 words — 2%
Crossref
- 2 preview-ovarianresearch.biomedcentral.com 93 words — 2%
Internet
- 3 www.ias.ac.in 40 words — 1%
Internet
- 4 [Tsili, A.C.. "Adnexal masses: Accuracy of detection and differentiation with multidetector computed tomography", Gynecologic Oncology, 200807](#) 23 words — < 1%
Crossref
- 5 eurradiolexp.springeropen.com 23 words — < 1%
Internet
- 6 eurorad.org 18 words — < 1%
Internet
- 7 [A. C. Tsili. "Comparative evaluation of multidetector CT and MR imaging in the differentiation of adnexal masses", European Radiology, 05/2008](#) 18 words — < 1%
Crossref
- 8 [Wanwangying Ma, Lin Chen, Yuming Zhou, Baowen Xu. "Do We Have a Chance to Fix Bugs](#) 16 words — < 1%

When Refactoring Code Smells?", 2016 International Conference on Software Analysis, Testing and Evolution (SATE), 2016

Crossref

9 Adel El-Badrawy, Eman Omran, Ashraf Khater, Mohamed Awad, Adel Helal. "64 Multidetector CT with multiplanar reformation in evaluation of bilateral ovarian masses", The Egyptian Journal of Radiology and Nuclear Medicine, 2012 15 words — < 1%

Crossref

10 ecommons.aku.edu 15 words — < 1%

Internet

EXCLUDE QUOTES OFF

EXCLUDE MATCHES OFF

EXCLUDE BIBLIOGRAPHY ON